



Noninvasive Porcelain Veneers: A Comprehensive Esthetic Approach

Paula de Carvalho Cardoso, DDS, MSc, PhD

Professor, Certification in Operative Dentistry Program of ABO-Goiás, Goiânia, Brazil.

Rafael de Almeida Decurcio, DDS, MSc

Professor, Certification in Operative Dentistry Program of ABO-Goiás, Goiânia, Brazil.

Júnio S. Almeida e Silva, DDS, MSc, PhD

Professor, Certification in Operative Dentistry Program of ABO-Goiás, Goiânia, Brazil; Professor, Operative Dentistry Division, University of Brasília, Brazil; Visiting Researcher, Department of Prosthodontics, Ludwig-Maximilians University, Munich, Germany.

Marcus Vinicius Perillo, DDS

Professor, Certification in Operative Dentistry Program of ABO-Goiás, Goiânia, Brazil.

Luiz Narciso Baratieri, DDS, MSc, PhD


Professor and Chair, Operative Dentistry Division, Federal University of Santa Catarina, Florianópolis, Brazil.

Porcelain is considered the most natural-looking material for the restoration of missing hard tissues and is available in a range of shades and translucencies. Clinicians have long sought conservative treatment approaches to restore anterior teeth with long-lasting and esthetic materials. This endeavor has been marked by new ceramic compositions and innovative restorative techniques. This article presents two case reports involving the use of ceramic veneers without tooth preparation, reinforcing the concept that noninvasive porcelain laminate veneers are a versatile and conservative treatment option in esthetic dentistry. (*Am J Esthet Dent* 2012;2:238–254.)

Correspondence to: Dr Júnio S. Almeida e Silva

Rua Natal 59 Ed. Villa-Lobos Apt 1801, Alto da Glória, Goiânia, Goiás, Brazil 75815705.

Email: juniosantos1710@yahoo.com.br



I ncreasing esthetic demands have led to the development of ceramic systems that wed esthetics with function. Additionally, conservative restorations such as porcelain veneers have gained popularity.^{1,2} In 1983 and 1984, Simonsen and Calamia^{3,4} showed that the bond strength of a hydrofluoric acid-etched and silanated veneer to porcelain was improved with the addition of a silane coupling agent. Since then, the successful clinical performance of adhesively luted porcelain veneers has been clinically proven,⁵⁻⁹ and these restorations now stand as an excellent restorative solution to provide long-lasting⁷ and esthetic results.



Ceramics are particularly well suited for veneer restorations and should be used primarily in conjunction with an additive approach to restore missing enamel; therefore, it is paramount that the ceramic system used can be bonded to the tooth substrate.¹⁰ Accordingly, pressed leucite and lithium disilicate–reinforced glass-ceramics offer favorable esthetic and mechanical properties,^{11,12} allowing for the fabrication of minimally invasive porcelain laminate veneers. This technique involves the use of thin porcelain laminate veneers (0.1 to 0.7 mm in thickness) placed on the visible portion of the enamel, with minimal or no tooth reduction.

Noninvasive porcelain veneers were initially recommended by Christensen¹³ and Quinn et al.¹⁴ As a result of the veneer's thinness, the color of the dental substrate may impair the final esthetic outcome. Several authors^{1,15,16} have reported that proper selection of the ceramic system requires the assessment of the color of the dental substrate and the thickness, degree of translucency, and masking ability of the ceramic material. In spite of the proven clinical success^{5,6} and esthetic characteristics of pressed leucite glass-ceramics, lithium disilicate–reinforced glass-ceramics provide better strength and respond better chromatically to discolored abutment teeth.^{17,18} To minimize the influence of the dental substrate on the final restoration color, bleaching prior to treatment or the use of different shades of resin cement is recommended. Since the choice of ceramic system for thin laminate porcelain veneers depends on several factors regarding the pa-

tient's condition and the quality of the remaining tissues, a thorough clinical examination and close communication with the dental laboratory are crucial for a predictable result.^{1,2,11}

This article presents two case reports involving the use of thin porcelain laminate veneers without tooth preparation.

NONINVASIVE PORCELAIN VENEERS: TREATMENT PLANNING

The esthetic and functional parameters of a given rehabilitation should be evaluated using a diagnostic wax-up and mock-up.¹⁹ Additionally, the dimensions of the central incisors must be evaluated by the clinician and communicated to the dental laboratory. The starting point for treatment planning is to determine the ideal width and length of the maxillary central incisors. Proper dominance of the central incisors must be ensured.²⁰ Determining these dimensions can be challenging, but Cesario and Latta²¹ have described one practical way to determine the proper width and length. Since the distance between the pupils (interpupillary distance) is a fixed reference of the face, the width of the maxillary central incisors can be assessed by measuring the interpupillary distance and dividing it by 6.6. To determine the length, the width is multiplied by 1.25.

The final proportions of the anterior teeth can be assessed and defined during the mock-up procedure. Thorough dentofacial, gingival, and tooth analysis can also be performed at this stage. For



the dentofacial analysis, careful attention should be paid to the lower third of the face. The face and lips form a static and dynamic frame for the teeth, with tooth exposure constantly changing during speaking and smiling.²⁰

To evaluate the static dentofacial aspect, the lips must be at rest and the maxillary anterior teeth should be visible, ranging from 1 to 5 mm of exposure depending on the thickness of the lips and the age and sex of the patient. The exposure of the maxillary teeth with the lips at rest should be approximately 3.4 mm for female patients and 1.9 mm for male patients. During aging, maxillary incisors may show reduced exposure as a result of physiologic or pathologic wear of the incisal edges and decreased muscle tone, which can alter the positions of the upper and lower lips.²²

To evaluate the dynamic dentofacial aspect, it is necessary to recognize possible disharmonies in the smile. Clinicians must be aware of the elements that characterize a harmonious smile, including (1) exposure of at least the second premolars while smiling, (2) absence of gingival recession and black triangles in the smile area, (3) gingival exposure of no more than 3 mm, (4) parallelism between the lower lip line and incisal edges of the maxillary anterior teeth, and (5) gentle contact between the incisal edge of the maxillary central incisors and the inner line of the lower lip while smiling.^{20,23}

The need for surgical correction of the gingival contour should also be evaluated using the mock-up. The architecture of the gingival margins can

significantly influence the esthetic appearance of the smile, especially in patients who present average or high smile lines. In individuals with low smile lines, disharmony at the gingival margins does not usually lead to esthetic problems; however, when the interdental papillae and gingiva are exposed during the smile, any irregularity or imbalance in alignment, contour, gingival symmetry, and zenith position can become noticeable. The gingival zenith is the most apical point of the gingival cervical contour and is typically located more distally along the axis of the maxillary anterior teeth.²³

An esthetically pleasing gingival contour is present when the gingival zenith of the maxillary central incisors is symmetric to that of the canines, whereas the lateral incisors' gingival zenith must be located approximately 1.5 mm below.²⁴ Preferably, the apical end of the distal vertical ridges of the maxillary central incisors should coincide with their gingival zenith. The balance of the gingival components (contour and zenith) generates imaginary lines that create a triangle, the vertices of which coincide with the gingival zeniths of the central incisors and canines. The lack of such an outline must be surgically corrected to avoid problems in regard to the tooth preparations (if required) and the restoration finish lines.^{22,23,25,26}

The proportions of the anterior teeth determine the balance and esthetic perception of the smile. A practical method to establish the width of the maxillary central incisors was discussed earlier in this article.²¹ As for the remaining anterior teeth, their dimensions are set



by the following guidelines^{26, 27}: (1) the crown width-length ratios of incisors and canines should be identical (77% to 86%), (2) the central incisors should be wider than the lateral incisors by approximately 2 to 3 mm and the canines by approximately 1 to 1.5 mm, (3) the canines should be wider than the lateral incisors by approximately 1 to 1.5 mm, and (4) the central incisors and canines should have similar crown heights (variation of only 0.5 mm) and be an average of 1 to 1.5 mm longer than the lateral incisors.

The incisal embrasures, which are also known as interincisal angles, are

V-shaped negative spaces between adjacent teeth at the mesioincisal and distoincisal angles of the anterior segment and are directly related to the position of interdental contact surfaces.^{23,28} The gingival embrasures are determined by the cervical portion of the contact point, the proximal surfaces of the adjacent teeth, and the interdental bone crest. Ideally, this pyramidal space should be filled by the interdental papilla, but its presence or absence is directly correlated with the distance between the contact point and bone crest. When this distance is less than or equal to 5 mm, the papilla

CASE REPORTS

The following cases reports were carried out according to the same clinical protocol, which included surgical correction of the gingival contour, tooth bleaching, and placement of noninvasive thin lithium disilicate–reinforced porcelain veneers. Noninvasive porcelain veneers enable the maintenance of biomimetic principles between ceramic and enamel. According to Magne and Douglas,³² a tooth restored with a porcelain laminate veneer recovers its coronal stiffness by 89% to 96% in comparison with a healthy tooth. Thus, porcelain laminate veneers are an excellent combination of hardness, resistance, and resilience.³²

In the first clinical case, a 19-year-old male patient presented with dissatisfaction regarding his smile (Figs 1 and 2). Clinical examination and intraoral photographs revealed small generalized diastemata at the maxillary anterior teeth. At the periodontal evaluation, no pathologic probing depths were detected, but a pronounced imbalance of the gingival contour was evident. The occlusal examination revealed a normal Class 1 molar occlusion, with functional canine and incisal guidance. No signs of parafunction were observed.

In the second case, a 19-year-old female also reported dissatisfaction with her smile (Figs 3 and 4). Clinical examination and intraoral photographs showed normal occlusion and the pres-



is present in 100% of cases. When this distance is 6 mm, the papilla is present in 56% of cases. When this distance is equal to or greater than 7 mm, the papilla is present in 27% of cases.²⁹

The vertical ridges, which are also known as brightness lines, delimit the facial flat area of the tooth (ie, the space between the mesial and distal vertical ridges), which is a strategic area for light reflection. Deviation of the vertical ridges on the labial tooth surface influences color perception because it modifies the flat area, thus modulating the pattern of light reflection. By decreasing the flat area, less light reflection will oc-

cur, thus creating an optical illusion of a narrower tooth. Increasing the flat area will create the opposite effect.^{28,30,31}

All aforementioned esthetic evaluations must be carried out to provide the dental technician with enough information regarding the planned smile rehabilitation. After the mock-up has been defined according to these esthetic criteria and the patient has approved the proposed treatment, a transfer impression of the mock-up in situ should be taken and sent to the laboratory. Additionally, a strict intraoral and extraoral photographic protocol is essential to envisioning the final esthetic results.

ence of small generalized diastemata at the maxillary anterior teeth. No signs of periodontal disease were present, but a slight imbalance of the gingival contour was observed.

In both cases, the mock-up was fabricated to serve as a reference for the smile configuration and the surgical correction of the gingival contour (Fig 5). Ninety days after their respective surgeries, the patients were ready for the restorative treatment (Fig 6).

Impression procedures

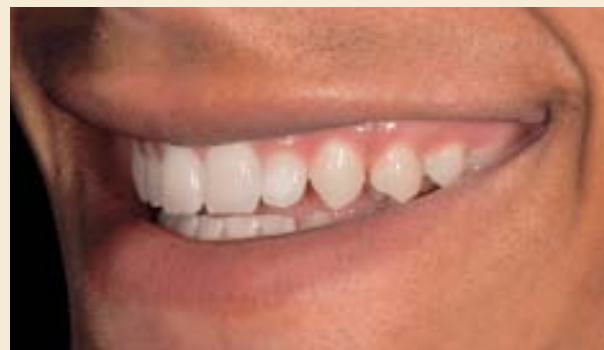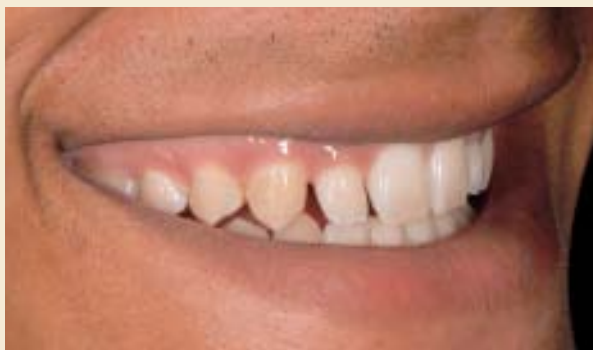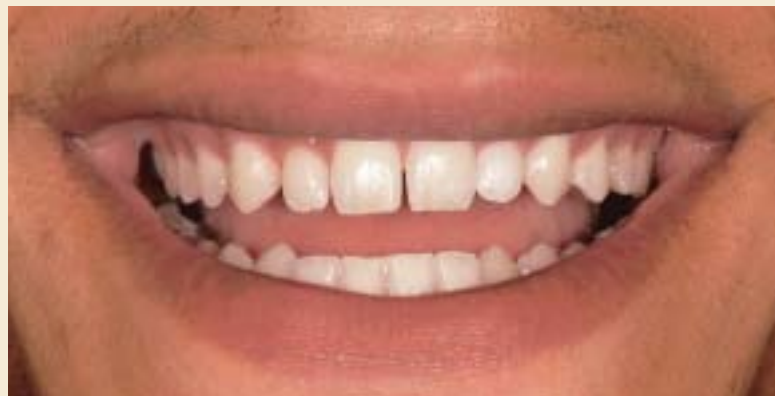To obtain a high-quality impression, addition silicone materials (vinyl polysiloxane) are recommended due to their elasticity and resistance to tearing.

They also allow multiple pours, which is essential for fabrication of adequate master casts.³³

A double-cord technique was used. A small-diameter compression cord (no. 00, Ultrapak, Ultradent) was placed in the bottom of the sulcus. A more superficial and thicker deflection cord (no. 0, Ultrapak) was inserted at the entrance of the sulcus, and deflection of the gingival sulcus was carried out for 4 minutes as the deflection cord expanded due to water sorption. The first compression cord must remain in place during the impression procedure to seal the sulcus and limit the flow of crevicular fluid, whereas the deflection cord is removed after four minutes of deflection (Figs 7a and 7b).



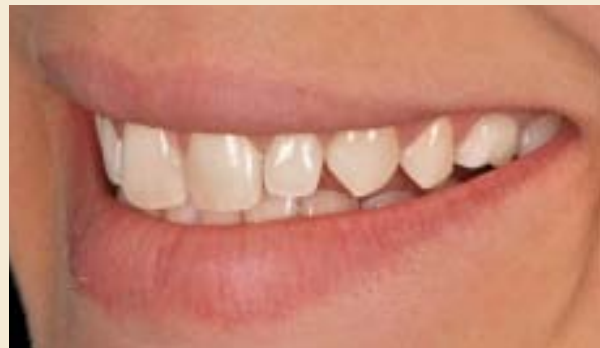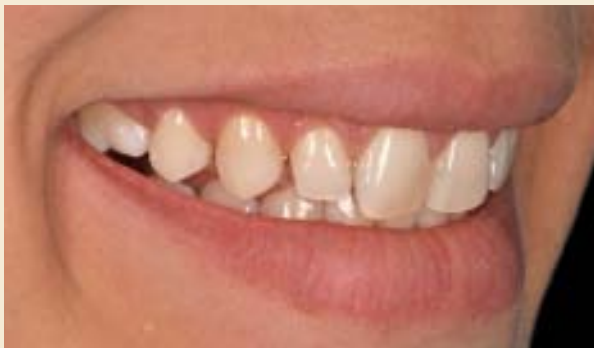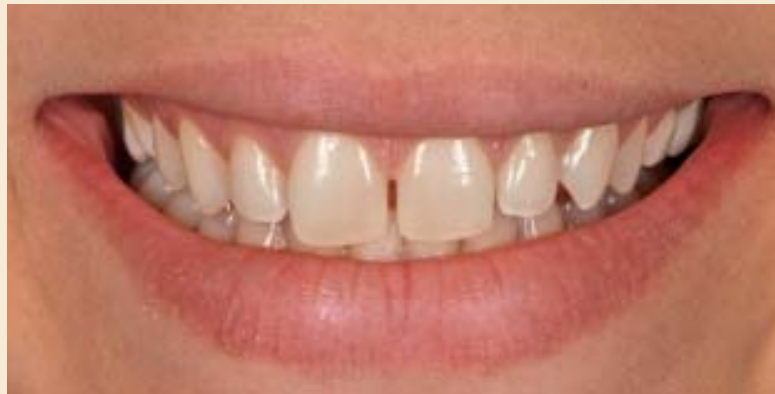Figs 1a to 1c Preoperative facial views of patient 1.



Figs 2a to 2c Preoperative extraoral views of patient 1. (a) Note the high maxillary posterior smile line and low anterior smile line. Also observe the lack of parallelism between the incisal edges of the maxillary anterior teeth and the lower lip. (b and c) Lateral views showing how the maxillary posterior smile line stands out, revealing more than 3 mm of gingival exposure.



Figs 3a to 3c Preoperative facial views of patient 2.



Figs 4a to 4c Preoperative extraoral views of patient 2. (a) Note the presence of diastemata between the maxillary central incisors. Also observe the lack of parallelism between the incisal edges of the maxillary anterior teeth and the lower lip. (b and c) Lateral views showing the generalized diastemata and the axial misalignment of the central incisors.

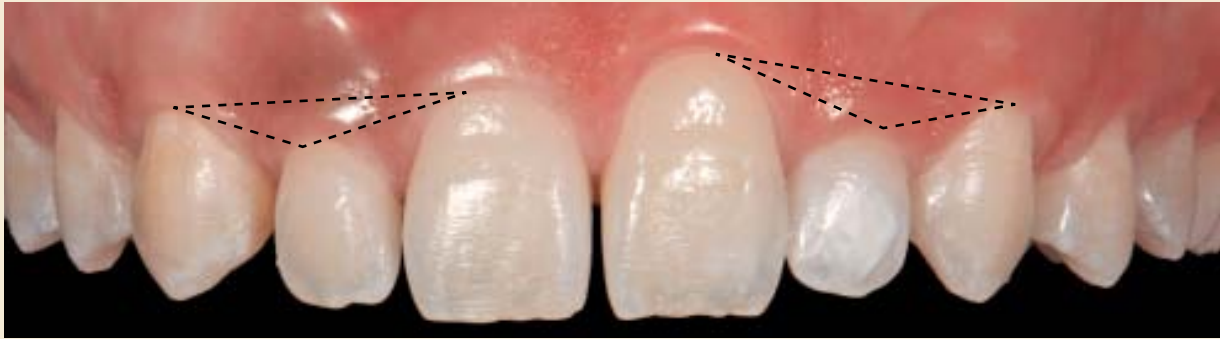

Fig 5a The interaction of the gingival contour and zenith creates imaginary lines that form a triangle (*dotted lines*). Note the discrepancy in gingival levels between both lateral incisors and their neighboring teeth as well as the height mismatch of the zeniths of the central incisors and canines.

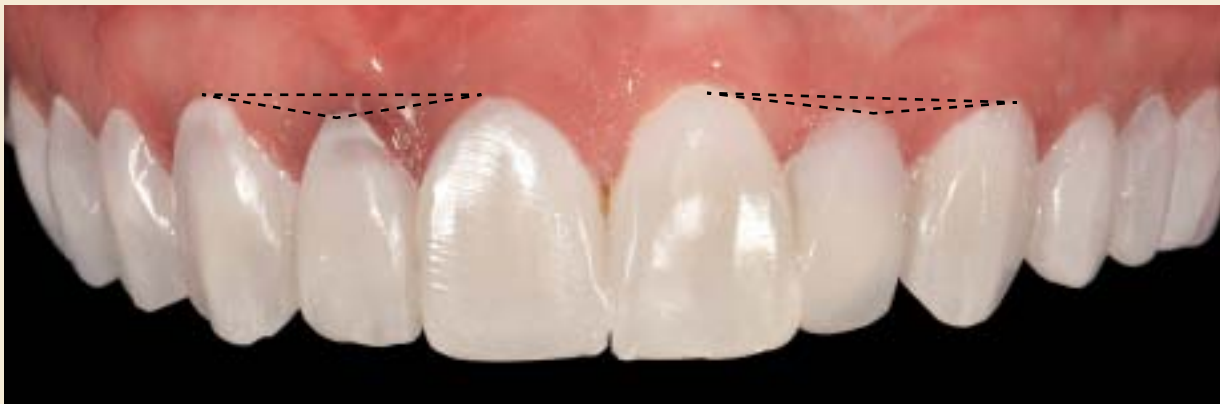

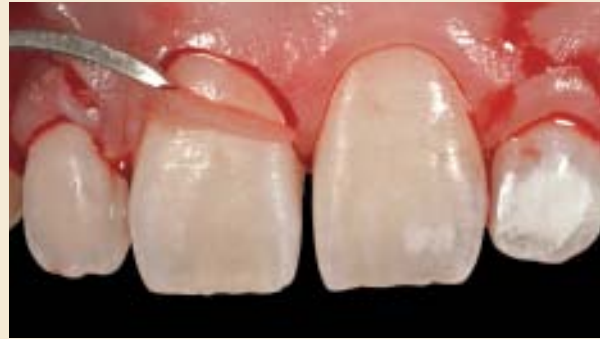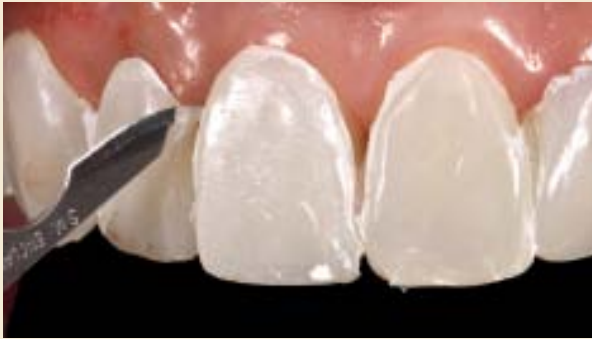Fig 5b Preoperative mock-up. Although the zenith of the maxillary right central incisor was located slightly more apical than the left central incisor, this discrepancy was disregarded due to the low smile line.

A one-step, double-mix impression technique was carried out. The deflection cord was removed from the teeth. Due to the viscoelastic behavior of the gingival sulcus, it remained deflected after removing the cord. It is important to emphasize that the deflection cord must be wet during removal so that it does not attach to the inner walls of the gingival sulcus, which can lead to bleeding. After removing the deflection cord, the gingival sulcus was air dried, and the light-body impression material was inserted throughout the gingival sulcus

to penetrate into the sulcus. Gentle air was blown onto the light-body material, ensuring penetration into the sulcus (Fig 7c). A full-mouth metallic tray was loaded with the heavy-body impression material, inserted in the patient's mouth for 5 minutes, and then removed.

Placement of the definitive restorations

After 2 weeks, the patients returned for placement of the final ceramic restorations (Figs 8a and 8b). Before initiating



Figs 5c and 5d Esthetic gingivectomy using the flapless technique. After determining the incision outline using the direct mock-up, the gingival collars were removed.

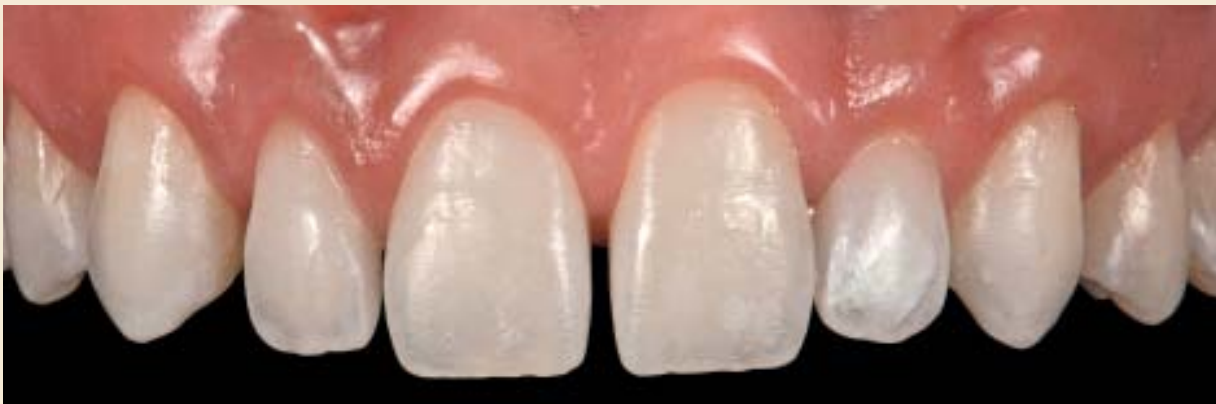
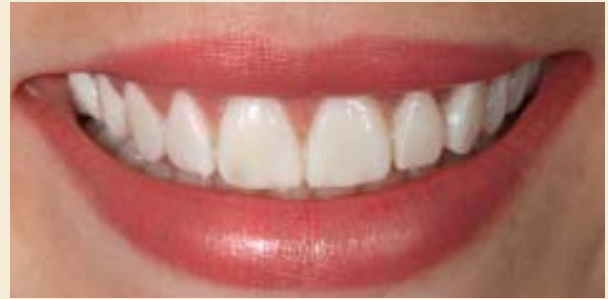
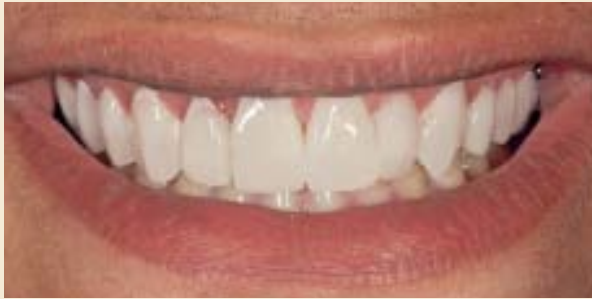Fig 5e Postoperative view 90 days after the gingivectomy.

the luting procedures, try-in of the final restorations was carried out. The teeth were cleaned with pumice and dried. Transparent try-in paste (Variolink II Try In, Ivoclar Vivadent) was applied, and any excess was removed with a spatula. The adaptation of the restorations was checked with a probe, and the patient used a mirror to assess the esthetic features of the treatment.

Adequate surface treatment for dental hard tissues and ceramics is crucial for successful bonding of porcelain restorations. The ceramic restorations

were placed on addition silicone, which was manipulated and placed into Dappen dishes. After setting, the addition silicone was removed so that the restorations were attached within it. This provided protection of the glazed external ceramic surfaces and facilitated handling of the restorations during surface treatment. Hydrofluoric acid (9%) was applied to the inner walls of the restorations for 20 seconds. After rinsing, the ceramic residues and remineralized salts were eliminated by rinsing and air drying for 20 seconds.



Figs 6a and 6b Postsurgery mock-up for (a) patient 1 and (b) patient 2.

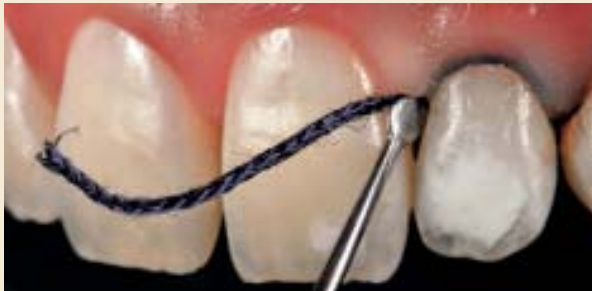

Fig 7a Impression taking. A small-diameter compression cord was placed in the bottom of the sulcus of each tooth.

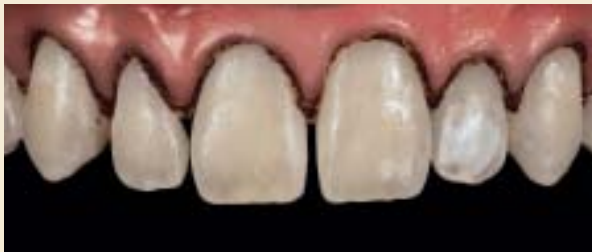

Fig 7b A more superficial, thicker, and continuous deflection cord was inserted in the entrance of the sulcus of all teeth.

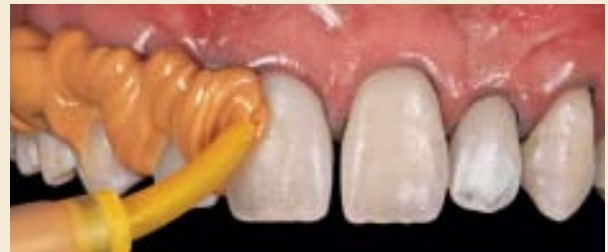
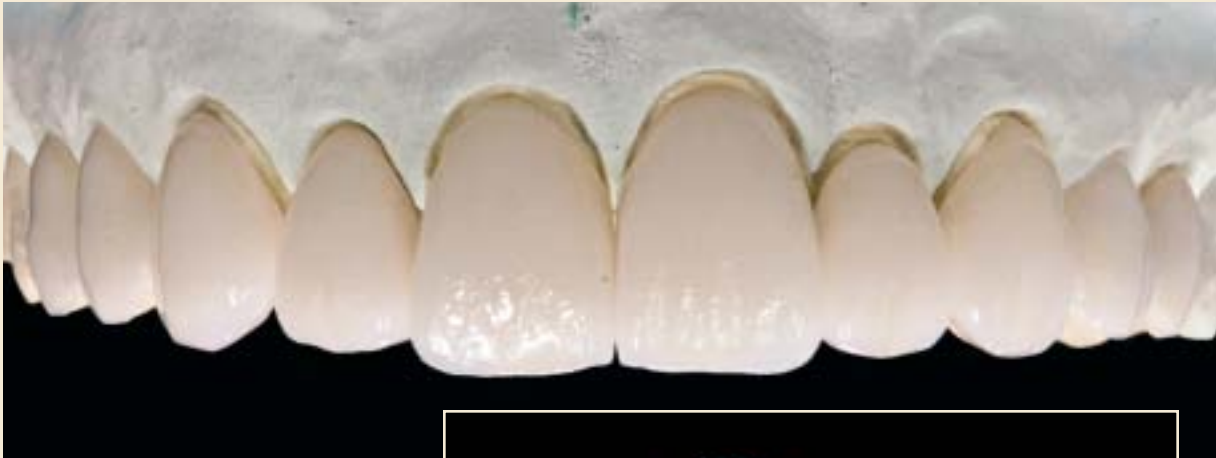
Fig 7c Insertion of the light-body impression material after removal of the deflection cord.

With the aid of a microbrush, silane (a chemical coupling agent) was applied to the inner surfaces of the ceramic restorations and left for 1 minute (Fig 9).

The cementation sequence depends on the arrangement of the proximal contact points, which can be better controlled with relative isolation of the operatory field. Relative isolation was achieved with a compression cord inserted in the bottom of the each tooth's

gingival sulcus, and the conditioning of the preparations surfaces was carried out following the two-step etch-and-rinse technique. First, 35% phosphoric acid was applied on the labial surfaces of the teeth for 30 seconds (Figs 10a and 10b). After rinsing and air drying, a dual-curing adhesive (Excite DSC, Ivoclar Vivadent) was rubbed against the tooth surfaces, followed by gentle air thinning, and left unpolymerized



Figs 8a and 8b Noninvasive porcelain veneers (e.max, Ivoclar Vivadent).

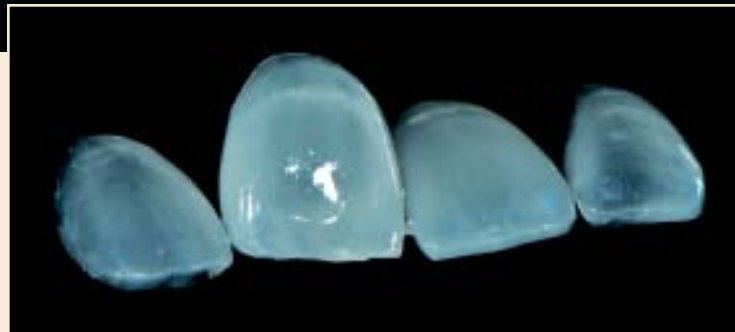
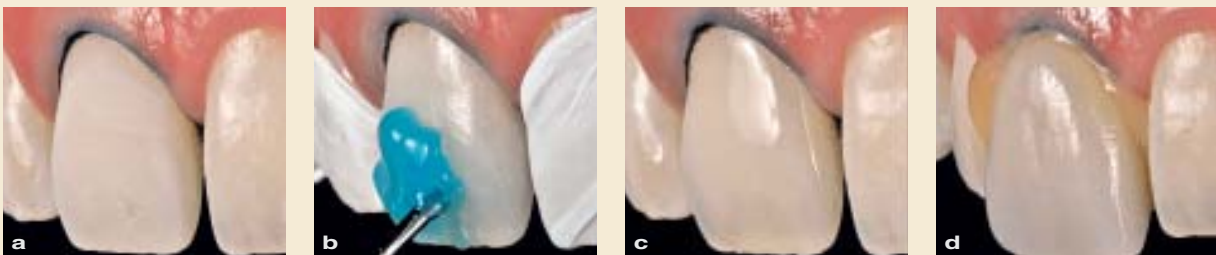
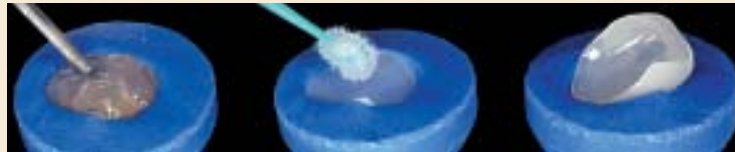Fig 9 Surface treatment of the restorations using 9% hydrofluoric acid and silane coupling agent.



Figs 10a to 10d Luting procedures: (a) relative isolation with compression cord; (b) 35% phosphoric acid etching; (c) application of the unpolymerized adhesive; (d) placement of the noninvasive porcelain restoration.

(Fig 10c). Meanwhile, a coat of the adhesive (Excite DSC) was applied to the inner walls of the restorations, which were then loaded with the transpar-

ent paste (Variolink II). The restorations were slowly seated with gentle finger pressure along the insertion axis (Fig 10d). Excess resin cement was

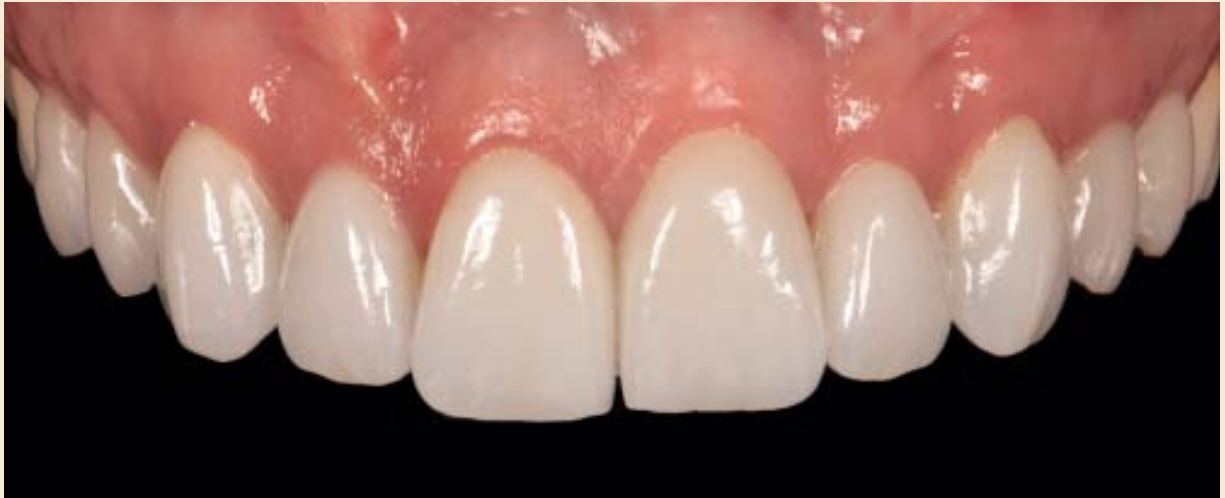

Fig 11 Intraoral view of patient 1 immediately after luting.



Figs 12a to 12c Final facial views of patient 1.

removed with a spatula, which was guided in a cutting motion parallel to the margin to avoid extraction of cement from the marginal joint. Flossing should be avoided before light activa-

tion because it can dislocate or detach the ceramic workpiece from the teeth. Light curing was performed at the facial, incisal, and palatal surfaces for 90 seconds each. The gingival cord

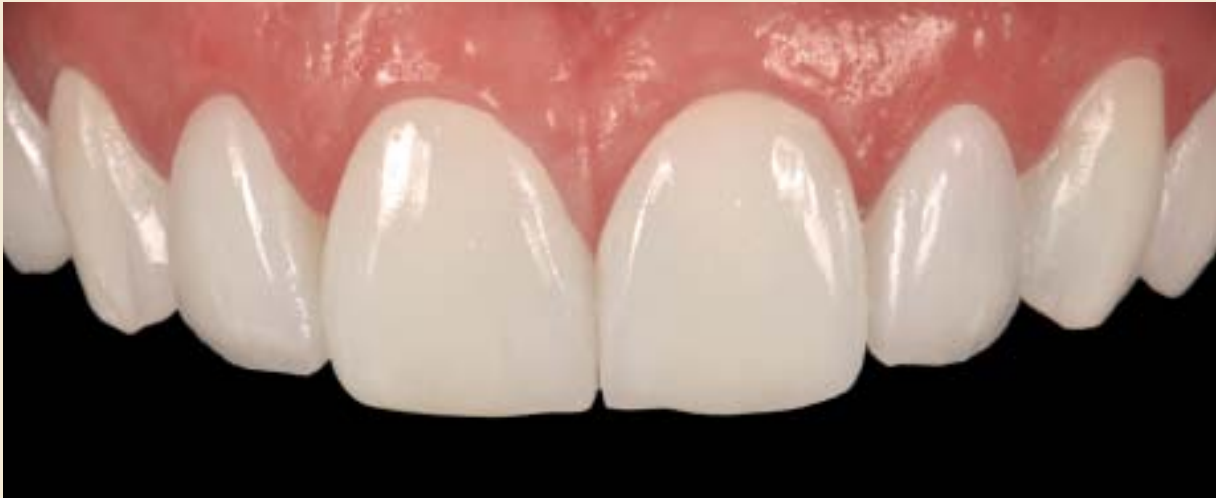

Fig 13 Intraoral view of patient 2 immediately after luting.



Figs 14a to 14c Final facial views of patient 2.

was then removed using dental pincers, and excess resin cement was chipped off with a no. 12 surgical blade. Refined finishing and polishing were performed at a subsequent session. The final re-

sults of both clinical cases are shown in Figs 11 to 14. Table 1 lists several key differences between conventional porcelain veneers and noninvasive porcelain veneers.

**Table 1** Noninvasive vs conventional porcelain veneers

	Noninvasive porcelain veneers	Conventional porcelain veneers
	Highly conservative	Conservative
Indications	Small corrections of incisal chipping, tooth fracture, conoid teeth, and diastemata	Mild stained teeth, alteration of mesiodistal and buccopalatal position
Preparation	None	Cervical third: 0.3 to 0.5 mm; Middle third: 0.6 to 1.0 mm; Incisal third: 1.0 to 2.1 mm
Restoration margins	Supragingival	Supra- and subgingival
Provisional restorations	No	Yes
Impressions	Retraction cords not always necessary	Retraction cords necessary
Laboratory technique	Very difficult	Difficult
Patient compliance	Minimal stress on patients	Greater stress on patients due to time needed for clinical procedures, preparations, and provisionals
Fractures	More likely during laboratory stage, try-in procedures, and luting due to the veneer's thinness	Less likely
Cementation	Very difficult	Difficult



CONCLUSIONS

Noninvasive porcelain laminate veneers represent an extremely conservative treatment option with excellent esthetic results when performed in accordance with a well-defined treatment plan and following strict diagnostic, laboratory, and clinical steps.

ACKNOWLEDGMENTS

Special thanks to Wilmar Porfírio (DentArt Laboratory, Goiânia, Goiás, Brazil) for fabricating the porcelain restorations. The authors also express sincere appreciation to Dudu Medeiros, who captured the facial photographs of the patients. The authors reported no conflicts of interest related to this study.

REFERENCES

- Almeida e Silva JS, Rolla JN, Edelhoff D, Araújo E, Baratieri LN. All-ceramic crowns and extended veneers in anterior dentition: A case report with critical discussion. *Am J Esthet Dent* 2011;1:60–81.
- Sadowsky SJ. An overview of treatment considerations for esthetic restorations: A review of the literature. *J Prosthet Dent* 2006;96:433–442.
- Simonsen RJ, Calamia JR. Tensile bond strength of etched porcelain [abstract 1154]. *J Dent Res* 1983;62:297.
- Calamia JR, Simonsen RJ. Effect of coupling agents on bond strength of etched porcelain [abstract 79]. *J Dent Res* 1984;63:179.
- Guess PC, Stappert CFJ. Midterm results of a 5-year prospective clinical investigation of extended ceramic veneers. *Dent Mater* 2008;24:804–813.
- Bona Della A, Kelly JR. The clinical success of all-ceramic restorations. *J Am Dent Assoc* 2008;139(suppl):8S–13S.
- Fradeani M, Redemagni M, Corrado M. Porcelain laminate veneers: 6- to 12-year clinical evaluation—A retrospective study. *Int J Periodontics Restorative Dent* 2005;25:9–17.
- Fradeani M. Six-year follow-up with Empress veneers. *Int J Periodontics Restorative Dent* 1998;18:216–225.
- Beier US, Kapferer I, Burtscher D, Dumfahrt H. Clinical performance of porcelain laminate veneers for up to 20 years. *Int J Prosthodont* 2012;25:79–85.
- Peumans M, Van Meerbeek B, Lambrechts P, Vanherle G. Porcelain veneers: A review of the literature. *J Dent* 2000;28:163–177.
- Kelly JR, Benetti P. Ceramic materials in dentistry: Historical evolution and current practice. *Aust Dent J* 2011;56(suppl 1):84–96.
- Conrad HJ, Seong W-J, Pesun IJ. Current ceramic materials and systems with clinical recommendations: A systematic review. *J Prosthet Dent* 2007;98:389–404.
- Christensen GJ. Veneering of teeth. State of the art. *Dent Clin North Am* 1985;29:373–391.
- Quinn F, McConnell RJ, Byrne D. Porcelain laminates: A review. *Br Dent J* 1986;19:61–65.
- Jorgenson MW, Goodkind RJ. Spectrophotometric study of five porcelain shades relative to the dimensions of color, porcelain thickness, and repeated firings. *J Prosthet Dent* 1979;42:96–105.
- Volpato CAM, Monteiro S, de Andrada MC, Fredel MC, Petter CO. Optical influence of the type of illuminant, substrates and thickness of ceramic materials. *Dent Mater* 2009;25:87–93.
- Edelhoff D, Brix O. All-ceramic restorations in different indications: A case series. *J Am Dent Assoc* 2011;142(suppl 2):14S–19S.
- Edelhoff D, Güth JF, Lungwirth F, et al. Light transmission through lithium-disilicate ceramics with different levels of translucency [abstract 3660]. *J Dent Res* 2010;special issue B:89.
- Vailati F, Belser UC. Full-mouth adhesive rehabilitation of a severely eroded dentition: The three-step technique. Part 1. *Eur J Esthet Dent* 2008;3:30–44.
- Fradeani M. Evaluation of dentolabial parameters as part of a comprehensive esthetic analysis. *Eur J Esthet Dent* 2006;1:62–69.
- Cesario VAV, Latta GHG. Relationship between the mesiodistal width of the maxillary central incisor and interpupillary distance. *J Prosthet Dent* 1984;52:641–643.
- Ahmad I. Anterior dental aesthetics: Dentofacial perspective. *Br Dent J* 2005;199:81–88.
- Ahmad I. Anterior dental aesthetics: Gingival perspective. *Br Dent J* 2005;199:195–202.
- Paris JC, Ortet S, Larmy A, Brouillet JL, Faucher AJ. Smile esthetics: A methodology for success in a complex case. *Eur J Esthet Dent* 2011;6:50–74.



25. Donovan TE, Chee WWL. Cervical margin design with contemporary esthetic restorations. *Dent Clin North Am* 2004; 48:417–431.
26. Magne P, Belser U. Natural oral esthetics. In: *Bonded Porcelain Restorations in the Anterior Dentition: A Biomimetic Approach*. Chicago: Quintessence, 2002:57–96.
27. Sterrett JD, Oliver T, Robinson F, Fortson W, Knaak B, Russell CM. Width/length ratios of normal clinical crowns of the maxillary anterior dentition in man. *J Clin Periodontol* 1999; 26:153–157.
28. Ahmad I. Anterior dental aesthetics: Dental perspective. *Br Dent J* 2005;199:135–141.
29. Tarnow DP, Magner AW, Fletcher P. The effect of the distance from the contact point to the crest of bone on the presence or absence of the interproximal dental papilla. *J Periodontol* 1992;63:995–996.
30. Touati B. The sense of beauty. Practical procedures and aesthetic dentistry. *Pract Proced Aesthet Dent* 2002; 14:16.
31. Magne P, Magne M, Belser U. The esthetic width in fixed prosthodontics. *J Prosthodont* 1999;8:106–118.
32. Magne P, Douglas WH. Cumulative effects of successive restorative procedures on anterior crown flexure: Intact versus veneered incisors. *Quintessence Int* 2000;31:5–18.
33. Johnson GH, Craig RG. Accuracy of addition silicones as a function of technique. *J Prosthet Dent* 1986;55: 197–203.

Copyright of American Journal of Esthetic Dentistry is the property of Quintessence Publishing Company Inc. and its content may not be copied or emailed to multiple sites or posted to a listserv without the copyright holder's express written permission. However, users may print, download, or email articles for individual use.